



PATIENT

Philly Abley

SPECIES

Canine

BREED

Havanese

SEX

F

AGE

8mo

WEIGHT

lbs

INTERPRETED BY

Maggie Machen Lamy,
DVM, DACVIM
(Cardiology)

IMAGING PERFORMED BY

HOSPITAL NAME

Rockaway AH

REFERRING VET

Dr. Maniar

INVOICE

23937

DATE

4/28/22

PRESENTING CLINICAL SIGNS

History: Arrhythmia noted during pre-op exam. Echo WNL.
Holter (1/25/22 KB): Frequent single APCs (2635). No VPCs
Current medications: None

HOLTER MONITOR FINDINGS AND RHYTHM ASSESSMENT

Time analyzed	23:48h
Mean heart rate	101bpm
Maximum heart rate	284bpm
Minimum heart rate	54bpm
VPCs	0
APCs	712; singles only.

Interpretation: Underlying normal sinus rhythm with appropriate rate variation. During sleep, occasional 2nd degree AV block is noted. Isolated APCs throughout; significantly less frequency than the prior recording.

Rhythm diagnosis: Sinus rhythm with infrequent APCs. Occasional 2nd degree AV block.

RECOMMENDATIONS

Compared to the prior recording there is evidence of significant improvement. Imperatively frequency of APCs has decreased significantly with consistently only single beats identified. Occasional AV block is noted while sleeping however this is considered a normal response in a healthy dog. No additional issues are identified

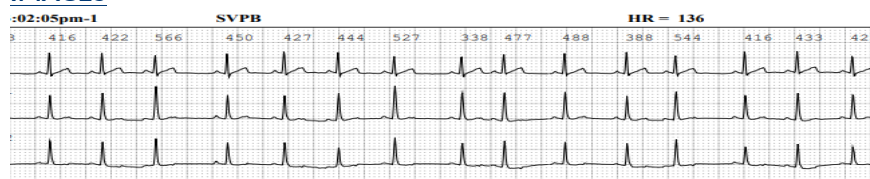
Given improvement seen here, it is worth noting that the patient was somewhat restricted during this tracing due to a muscle injury. This may suggest the arrhythmia occurs more frequently with excitement/exertion, or may reflect a true improvement. Regardless, what is seen here is largely benign and no treatment is warranted.

The cause of the APCs in this young dog remains unknown. As was mentioned in the prior report, a primary conduction abnormality is possible, or APCs may develop secondary to systemic issues. In an otherwise healthy puppy, the former is more likely. The patient may be at risk for rapid SVT development lifelong, and follow up monitoring is advised.

Anesthetic recommendations are unchanged from the prior holter report.

Going forward, reassessing in 1 year is recommended, sooner if any collapse or acute lethargy is noted.

IMAGES





PATIENT

Philly Abley

SPECIES

Canine

BREED

Havanese

SEX

F

AGE

8mo

WEIGHT

lbs

INTERPRETED BY

Maggie Machen Lamy,
DVM, DACVIM
(Cardiology)

**IMAGING
PERFORMED BY**

HOSPITAL NAME

Rockaway AH

REFERRING VET

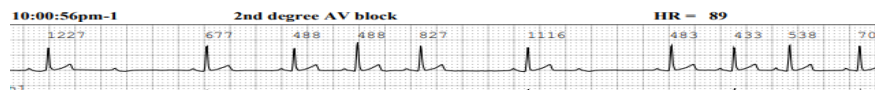
Dr. Maniar

INVOICE

23937

DATE

4/28/22



The information and recommendations provided are based on the images presented by the referring veterinarian. No evaluation can be communicated regarding pathology that was not visible in the image/video clips provided.

Thank you for this referral. If the clinical or image interpretation does not parallel your findings or if I can be of any further assistance please contact me.

Maggie Machen Lamy, DVM
Diplomate of the American College of Veterinary Internal Medicine (Cardiology)
info@sonopath.com